Pancreatology 16 (2016) 958–965

Contents lists available at ScienceDirect

Pancreatology

journal homepage: www.elsevier.com/locate/pan

Original Article

Factors and outcomes associated with pancreatic duct disruption in patients with acute necrotizing pancreatitis

Ji Woong Jang [a], Myung-Hwan Kim [b, *, 1], Dongwook Oh [b], Dong Hui Cho [b], Tae Jun Song [b], Do Hyun Park [b], Sang Soo Lee [b], Dong-Wan Seo [b], Sung Koo Lee [b], Sung-Hoon Moon [c, **, 1]

[a] Department of Internal Medicine, Eulji University College of Medicine, Eulji University Hospital, Daejeon, South Korea
[b] Department of Internal Medicine, University of Ulsan College of Medicine, Asan Medical Center, Seoul, South Korea
[c] Department of Internal Medicine, Hallym University College of Medicine, Hallym University Sacred Heart Hospital, Anyang, South Korea

ARTICLE INFO

Article history:
Received 4 June 2016
Received in revised form
8 August 2016
Accepted 20 September 2016
Available online 20 September 2016

Keywords:
Acute necrotizing pancreatitis
Pancreatic duct
Endoscopic retrograde cholangiopancreatography

ABSTRACT

Background and aims: Acute necrotizing pancreatitis (ANP) can affect main pancreatic duct (MPD) as well as parenchyma. However, the incidence and outcomes of MPD disruption has not been well studied in the setting of ANP.
Methods: This retrospective study investigated 84 of 465 patients with ANP who underwent magnetic resonance cholangiopancreatography and/or endoscopic retrograde cholangiopancreatography. The MPD disruption group was subclassified into complete and partial disruption.
Results: MPD disruption was documented in 38% (32/84) of the ANP patients. Extensive necrosis, enlarging/refractory pancreatic fluid collections (PFCs), persistence of amylase-rich output from percutaneous drainage, and amylase-rich ascites/pleural effusion were more frequently associated with MPD disruption. Hospital stay was prolonged (mean 55 vs. 29 days) and recurrence of PFCs (41% vs. 14%) was more frequent in the MPD disruption group, although mortality did not differ between ANP patients with and without MPD disruption. Subgroup analysis between complete disruption (n = 14) and partial disruption (n = 18) revealed a more frequent association of extensive necrosis and full-thickness glandular necrosis with complete disruption. The success rate of endoscopic transpapillary pancreatic stenting across the stricture site was lower in complete disruption (20% vs. 92%). Patients with complete MPD disruption also showed a high rate of PFC recurrence (71% vs. 17%) and required surgery more often (43% vs. 6%).
Conclusions: MPD disruption is not uncommon in patients with ANP with clinical suspicion on ductal disruption. Associated MPD disruption may influence morbidity, but not mortality of patients with ANP. Complete MPD disruption is often treated by surgery, whereas partial MPD disruption can be managed successfully with endoscopic transpapillary stenting and/or transmural drainage. Further prospective studies are needed to study these items.
© 2016 IAP and EPC. Published by Elsevier B.V. All rights reserved.

Main pancreatic duct (MPD) disruption with leakage of pancreatic juice can result from episodes of acute pancreatitis, chronic pancreatitis, pancreatic trauma, pancreatic malignancy, or pancreatic surgery [1–5]. In the setting of acute pancreatitis, pancreatic-duct disruption may develop in patients with severe or necrotizing pancreatitis, but not in those with interstitial edematous pancreatitis. Necrosis of cellular elements including ductal epithelial cells as well as acinar/islet cells, may develop in severe forms of acute pancreatitis. Consequently, pancreatic-duct disruption can lead to the extravasation of pancreatic juice and formation of pancreatic fluid collections (PFCs).

* Corresponding author. Department of Internal Medicine, University of Ulsan College of Medicine, Asan Medical Center, Asanbyeongwon-Gil 86, Songpa-gu, Seoul, 138-736, South Korea.
** Corresponding author. Department of Internal Medicine, Hallym University Sacred Heart Hospital, Hallym University College of Medicine, 896 Pyeongan-dong, Dongan-gu, Anyang, Gyeonggi-do, 431-070, South Korea.
E-mail addresses: mhkim@amc.seoul.kr (M.-H. Kim), endomoon@naver.com (S.-H. Moon).
[1] Myung-Hwan Kim and Sung-Hoon Moon contributed equally to this work as corresponding authors.

http://dx.doi.org/10.1016/j.pan.2016.09.009
1424-3903/© 2016 IAP and EPC. Published by Elsevier B.V. All rights reserved.

Downloaded from ClinicalKey.com at Italian Association of Gastroenterology (AIGO) December 26, 2016.
For personal use only. No other uses without permission. Copyright ©2016. Elsevier Inc. All rights reserved.

Previous studies that addressed this issue may be limited by their use of heterogeneous cohorts of patients with acute pancreatitis, chronic pancreatitis, or post-surgical fistulas [6,7]. The failure rates of endoscopic treatment and the recurrence rates of PFCs caused by pancreatic-duct disruptions are both generally higher in patients with chronic pancreatitis than with acute pancreatitis, because of a frequent association with ductal strictures/calculi in the downstream duct [6]. Data on the pancreatic-duct disruptions specifically in patients with acute necrotizing pancreatitis (ANP) are limited when compared with other causes of pancreatic-duct disruptions.

In the setting of ANP, the clinicians often concentrate on parenchymal necrosis and its consequences such as walled-off necrosis (WON). However, the associated pancreatic-duct disruptions can worsen underlying pancreatitis and affect overall outcomes. A subset of patients with ANP may show the brunt of the disease on the duct (*i.e.,* disruptions/leaks) and not on glandular tissue (*i.e.,* parenchymal necrosis *per se*). Previous study demonstrated that pancreatic ductal changes may predict spontaneous resolution, success of non-operative measures, and direct therapies for PFCs [8]. Despite the burgeoning literature on the technical details required to perform endoscopic necrosectomy for WON [9,10], relatively few studies have focused on issues surrounding the presence and outcomes of MPD disruption in the context of ANP [1,11]. The aim of the present study was to evaluate the predictors, clinical consequences, and outcomes of concomitant MPD disruption/leakage in patients with ANP. The management of WON itself and detailed techniques for the drainage of PFCs are beyond the scope of our study aim.

1. Materials and methods

1.1. Patients

Between 2005 and 2013, 5756 patients with acute pancreatitis were identified through a discharge diagnosis code from data of Asan Medical Center in Korea. Among them, 465 patients were categorized as ANP in a discharge diagnosis code. All of these ANP patients had pancreatic or peripancreatic necrosis on contrast-enhanced computed tomography (CECT). Among these patients, 21 patients with isolated peripancreatic necrosis and 360 patients who had undergone neither endoscopic retrograde cholangiopancreatography (ERCP) nor magnetic resonance cholangiopancreatography (MRCP) were excluded (Fig. 1). Ultimately, this study consisted of 84 ANP patients who underwent MRCP and/or ERCP. This study was approved by our institutional review board.

1.2. Nomenclature and definitions

Acute pancreatitis was classified as mild, moderately severe, or severe according to the revised Atlanta classification [12]. Initial CECT scan was usually performed 5–7 days after onset of symptoms. ANP was defined as a lack of enhancement of pancreatic parenchyma and/or peripancreatic tissue on CECT scan [9]. Follow-up CT was performed in the case with 1) clinical deterioration, 2) as needed after intervention, and 3) 1–2 months after onset of symptoms. Infected necrosis was confirmed when extraluminal gas in the pancreatic and/or peripancreatic tissues was apparent on CECT or when fine-needle aspiration (FNA) was positive for bacteria and/or fungi on Gram stain and culture, with clinical and biochemical deterioration of the patients [12].

1.2.1. Parenchymal necrosis and pancreatic fluid collections (PFCs)

The extent of necrosis in the parenchyma was categorized as <30%, 30–50%, or >50%, based on the Balthazar CT severity index [13]. Full-thickness glandular necrosis of the pancreas was presumed when the expected course of the MPD was completely transected perpendicularly to the long axis of the pancreas on CT scan due to the parenchymal necrosis of the entire width of the pancreatic segment (Supplementary Fig. 1). The location of necrosis

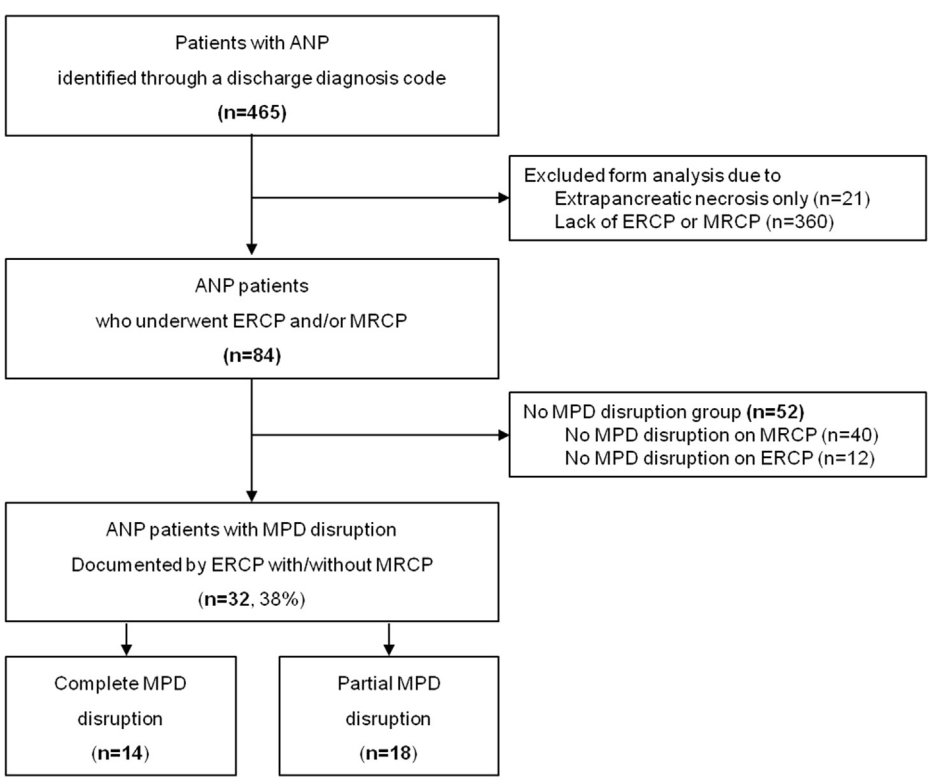

Fig. 1. Flow diagram of our patients selection. ANP, acute necrotizing pancreatitis; ERCP, endoscopic retrograde cholangiopancreatography; MRCP, magnetic resonance cholangiopancreatography; MPD, main pancreatic duct.

Downloaded from ClinicalKey.com at Italian Association of Gastroenterology (AIGO) December 26, 2016.
For personal use only. No other uses without permission. Copyright ©2016. Elsevier Inc. All rights reserved.

was classified as involving or not involving the pancreatic neck or proximal body. This area is vulnerable to ischemic injury involving the pancreatic-duct and parenchyma, or both, due to its unique vascular supply [14]. Our study did not include patients with isolated peripancreatic necrosis because we wanted to evaluate the patients with ANP and concomitant MPD disruption within the zone of parenchymal necrosis.

PFCs develop secondary to either fluid leakage from the pancreas or liquefaction of pancreatic necrosis. The revised Atlanta classification provides characterization of PFCs based on the presence of necrosis and the time from injury, but CECT cannot reliably detect necrotic debris within a PFC. Actually, WON has sometimes been misdiagnosed as pseudocyst in previous studies [15]. Our study therefore used the term "PFCs" without discrimination between WON and pseudocyst.

1.2.2. Suspicion of MPD disruption and subsequent ductal imaging

A disrupted duct was suspected in cases with enlarging/refractory PFCs or when there was persistent catheter drainage of amylase-rich fluid despite the resolution of the fluid collection [16]. In patients with symptomatic large PFCs, ductal anatomy imaging such as MRCP/ERCP was generally performed after the drainage of PFCs for clarification of ductal visualization.

Regarding the timing of intervention, we postponed intervention more than 4 weeks after symptoms onset unless clinical deterioration developed, in order to allow collection to be encapsulated and liquefied. We employed a step-up approach with endoscopic/percutaneous drainage first and surgical debridement as the last resort.

1.2.3. MPD disruption

Disruption of MPD was defined as a loss of continuity of MPD with or without extravasation, and it could be further classified as partial or complete according to the degree of disruption. Partial disruption was asserted when the MPD could be opacified upstream from the disruption site during ERCP, whereas complete disruption was defined as an abrupt cut-off and/or extravasation of injected contrast medium without filling the upstream pancreatic duct [17]. An inability to traverse the disruption site with a guidewire was an additional evidence of complete disruption.

The parenchymal necrosis of the pancreatic segment involving the neck, body, or proximal tail can completely disconnect the upstream and downstream parts of the duct. Therefore, recurrent/unresolving PFCs or internal/external pancreatic fistulas can develop due to persistent leakage of pancreatic juice from an isolated viable upstream gland. This condition is called disconnected pancreatic duct syndrome (DPDS) [9]. In this study, complete pancreatic ductal disruption was used interchangeably with DPDS except for necrosis of the far distal end of the tail.

An absence of MPD disruption was determined by MRCP or ERCP, although the presence of MPD disruption was confirmed by ERCP. If MRCP clearly demonstrated an intact MPD from head to tail without discontinuity, this was regarded as no disruption, so ERCP was usually not performed in those patients. We included only disruption of the MPD, rather than that of the side branches, because a minute ductal leak of pancreatic juice from a side branch may resolve spontaneously without any intervention [7]. Secretin stimulation before MRCP was not used for our patients because secretin is not available in our country.

1.3. Statistical analysis

Fisher's exact test and the χ^2 test were used to compare categorical variables, and Student's t-test was used to compare continuous variables. $P < 0.05$ was considered statistically significant.

Table 1
Baseline characteristics of the study population.

	N = 84
Median age (range), years	48 (18–83)
Gender, M:F	70:14
Potential etiologies for pancreatitis, n (%)	
Alcohol	42 (50)
Gallstones	9 (11)
Post-ERCP	8 (10)
Post-surgical	3 (4)
Metabolic	2 (2)
Gene-associated	1 (1)
Medication	2 (2)
Idiopathic	17 (20)
Severity of acute pancreatitis, n (%)	
Mild	0 (0)
Moderately severe	56 (67)
Severe	28 (33)
Surgical treatment for ANP, n (%)	12 (14)
Pancreatitis-related mortality, n (%)	5 (6)
Median follow-up period (range), days	512 (35–3500)

ANP, acute necrotizing pancreatitis; ERCP, endoscopic retrograde cholangiopancreatography; MRCP, magnetic resonance cholangiopancreatography.

2. Results

2.1. Baseline characteristics of the study population

The median age was 48 years (range 18–83 years), and 83% were male (Table 1). Potential etiologies for acute pancreatitis included alcohol (n = 42), gallstones (n = 9), post-ERCP (n = 8), post-surgical (n = 3), metabolic (n = 2), gene-associated (n = 1), medication (n = 2), and idiopathic cause (n = 17). The severity of acute pancreatitis was classified as moderately severe in 56 (67%) patients and severe in 28 (33%) patients. Twelve patients underwent surgery for the treatment of ANP. Pancreatitis-related mortality was 6%. The first intervention (such as endoscopic/percutaneous drainage) was performed median 39 days (range 21–178 days) after symptoms onset. The median follow-up period was 512 days (range 35–3500 days).

2.2. The incidence, predictors, and clinical consequences of MPD disruption in the setting of ANP

Among the 84 ANP patients who underwent MRCP and/or ERCP, MPD disruption (complete 14; partial 18) was documented by ERCP in 32 (38%) patients. In the remaining 52 patients, 40 showed no MPD disruption on MRCP alone and 12 revealed no MPD disruption on ERCP with/without MRCP.

The clinical and radiologic characteristics of the 32 ANP patients with MPD disruption were compared with those of 52 ANP patients without MPD disruption (Table 2). Extensive necrosis of more than 50% of the pancreas was significantly higher in patients with MPD disruption (72% vs 46%, $p = 0.025$). Presentation with enlarging/refractory PFCs or persistence of amylase-rich high-volume output from percutaneous drainage (47% vs. 15%) accompanying amylase-rich ascites or unilateral pleural effusion (38% vs. 6%), was significantly higher in patients with MPD disruption. The median amylase level measured from the percutaneous catheter of the PFCs, pleural effusion, and ascites were 79,588 (range 7247–124,900) U/L, 6800 (1240–13,721) U/L, and 9200 (877–12,543) U/L, respectively. Mediastinal PFC was noted only in patients with MPD disruption (9% vs. 0%, $p = 0.052$). Patients with and without MPD disruption

Downloaded from ClinicalKey.com at Italian Association of Gastroenterology (AIGO) December 26, 2016.
For personal use only. No other uses without permission. Copyright ©2016. Elsevier Inc. All rights reserved.

Table 2
Comparison between 32 ANP patients with MPD disruption and 52 ANP patients without MPD disruption.

	ANP patients with MPD disruption (n = 32)	ANP patients without MPD disruption (n = 52)	P
Mean age (±SD), years	45 ± 16	49 ± 15	ns
Gender, M:F	27:5	43:9	ns
Etiologies of pancreatitis, n (%)			ns
Alcohol	14 (44)	28 (54)	
Other than alcohol	18 (56)	24 (46)	
Enlarging/refractory PFCs or Persistence of amylase-rich high-volume output from percutaneous drainage, n (%)	15 (47)	8 (15)	0.002
Amylase-rich ascites or unilateral pleural effusion, n (%)	12 (38)	3 (6)	0.001
Mediastinal PFCs, n (%)	3 (9)	0 (0)	0.052
Severity of acute pancreatitis, n (%)			ns
Moderately severe	24 (75)	32 (62)	
Severe	8 (25)	20 (38)	
Infected necrosis, n (%)	22 (69)	42 (81)	ns
Site of necrosis, n (%)			ns
Involving neck or proximal body	13 (41)	24 (46)	
Not involving neck or proximal body	19 (59)	28 (54)	
Extent of necrosis (>50%), n (%)	23 (72)	24 (46)	0.025
Need for ICU care, n (%)	11(34)	17(33)	ns
Mean hospital stay (±SD), days	55 ± 44	29 ± 30	0.005
Surgery for ANP treatment, n (%)	7 (22)	5 (10)	ns
Recurrent/refractory PFCs or recurrence of pancreatitis after initial treatment, n (%)	13 (41)	7 (14)	0.008
Pancreatitis-related mortality, n (%)	1 (3)	4 (8)	ns
Mean follow-up period (±SD), days	948 ± 863	810 ± 868	ns

ANP, acute necrotizing pancreatitis; MPD, main pancreatic duct; SD, standard deviation; ns, not significant; PFCs, pancreatic fluid collections; ICU, intensive care unit.

showed no statistical difference in the proportion of infected necrosis (69% vs. 81%).

The mean hospital stay was significantly longer in patients with MPD disruption (55 ± 44 days vs. 29 ± 30 days, $p = 0.005$). Recurrent/refractory PFCs or recurrence of pancreatitis after initial treatment was also significantly frequent in patients with MPD disruption (41% vs. 14%, $p = 0.008$). Patients with and without MPD disruption showed no difference in their need for ICU care, their surgical treatment, and their pancreatitis-related mortality.

2.3. The role of MRCP in the diagnosis of MPD disruption in patients with ANP

MRCP alone was performed in 40 ANP patients, ERCP alone was performed in 26, and both MRCP and ERCP were performed in 18. In the 18 patients who underwent both MRCP and ERCP (complete MPD disruption 8; partial MPD disruption 7; no disruption 3), the overall sensitivity of MRCP for detecting MPD disruption was 80% (12/15). When analyzed according to the degree of MPD disruption, 88% (7/8) of patients with complete MPD disruption were suspected as having MPD disruption on MRCP, whereas 71% (5/7) of partial MPD disruption were suspected on MRCP ($p = 0.5692$). All 3 ANP patients with intact MPD on ERCP also showed no disruption on MRCP.

2.4. Interventions for PFCs related with MPD disruption and treatment outcomes (Fig. 2)

2.4.1. Patients with complete MPD disruption

At initial admission, 22 cumulative drainage procedures for PFCs were performed on 14 patients with complete MPD disruption. Percutaneous drainage was most frequently used as an initial treatment modality (10/22), followed by endosonography (EUS)-guided transmural drainage (5/22). Transpapillary drainage was also attempted in 5 patients, but was successful in bridging across the stricture site in only one patient (1/5; 20%). Regarding the treatment for WON, endoscopic necrosectomy was performed for 5 patients. Distal pancreatectomy for DPDS was performed in 2 patients at initial admission.

A second admission occurred in 71% (10/14) of patients with complete MPD disruption due to recurrent/refractory PFCs or recurrence of pancreatitis. Recurrences were managed conservatively in 1 and surgically in 3 patients. EUS-guided direct pancreatic-duct drainage was performed in 1 patient with upstream duct dilatation as management for recurrence, but surgery was eventually required. The remaining 5 patients who were at high risk for surgery were managed with permanent percutaneous catheter drainage with a median duration of 540 days (range 303–1020 days) (Fig. 3).

2.4.2. Patients with partial MPD disruption

At initial admission, 3 patients with partial MPD disruption improved with supportive care only. The remaining 15 patients underwent 20 cumulative drainage procedures. Transpapillary drainage was the most frequently used (12/20) as an initial treatment modality, and was successful in 92% (Fig. 4). EUS-guided transmural drainage was performed in 6 patients, and percutaneous drainage in 2. Regarding the treatment for WON, endoscopic necrosectomy was performed for 3 patients.

A second admission occurred in 17% (3/18) of the patients with partial MPD disruption due to recurrent/refractory PFCs or recurrence of pancreatitis. One patient with partial MPD disruption, who improved initially with EUS-guided transmural stenting for PFC, developed an MPD stricture, possibly due to fibrosis, as part of the healing process after several months. This stricture was treated with transpapillary stenting. Overall, 2 of 3 patients with recurrences were successfully managed endoscopically, and the remaining 1 patient underwent surgery for uncontrolled infected necrosis.

Transpapillary stenting was performed using a 5F–10F conventional plastic stent placed with a median duration of 150 days (range 20–509 days). Transmural stenting was performed using 7F double pigtail stent(s) or an 8–10 mm fully covered metal stent placed with a median duration of 154 days (range 54–428 days).

Downloaded from ClinicalKey.com at Italian Association of Gastroenterology (AIGO) December 26, 2016.
For personal use only. No other uses without permission. Copyright ©2016. Elsevier Inc. All rights reserved.

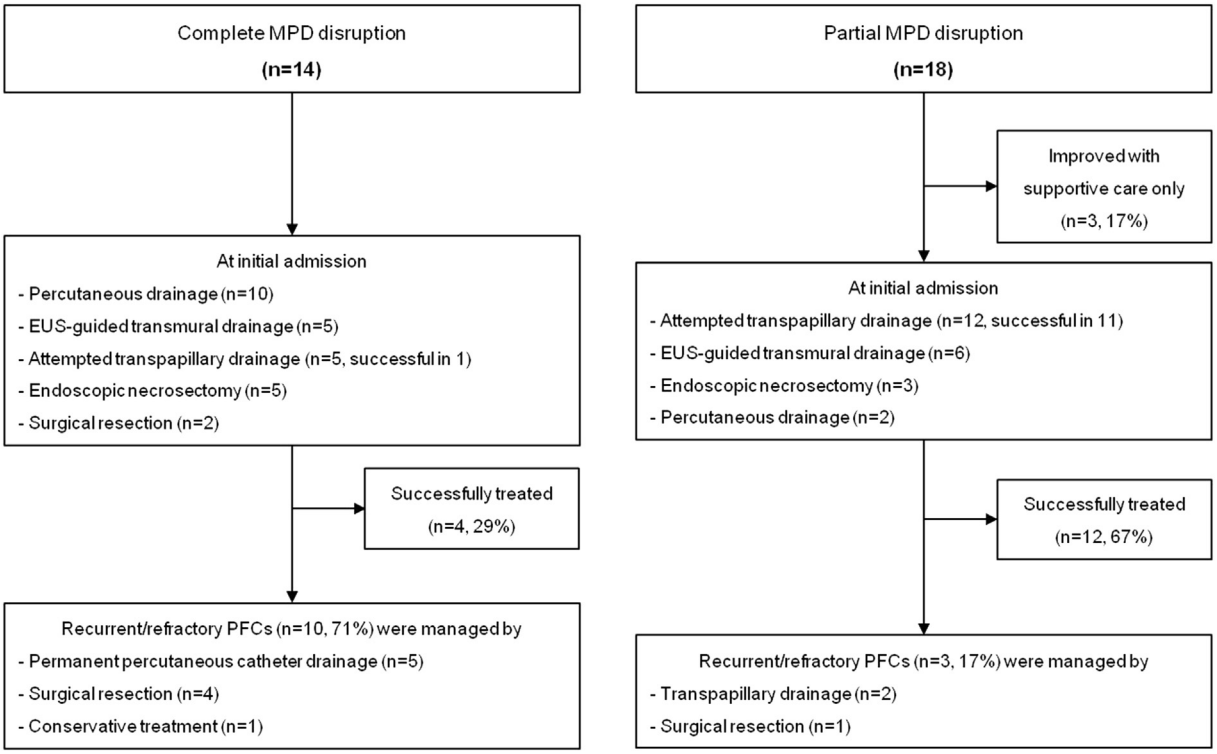

Fig. 2. Interventions for PFCs related with MPD disruption and treatment outcomes. PFC, pancreatic fluid collection; MPD, main pancreatic duct; EUS, endosonography. *The patient underwent surgery due to necrosectomy for uncontrolled infected necrosis.

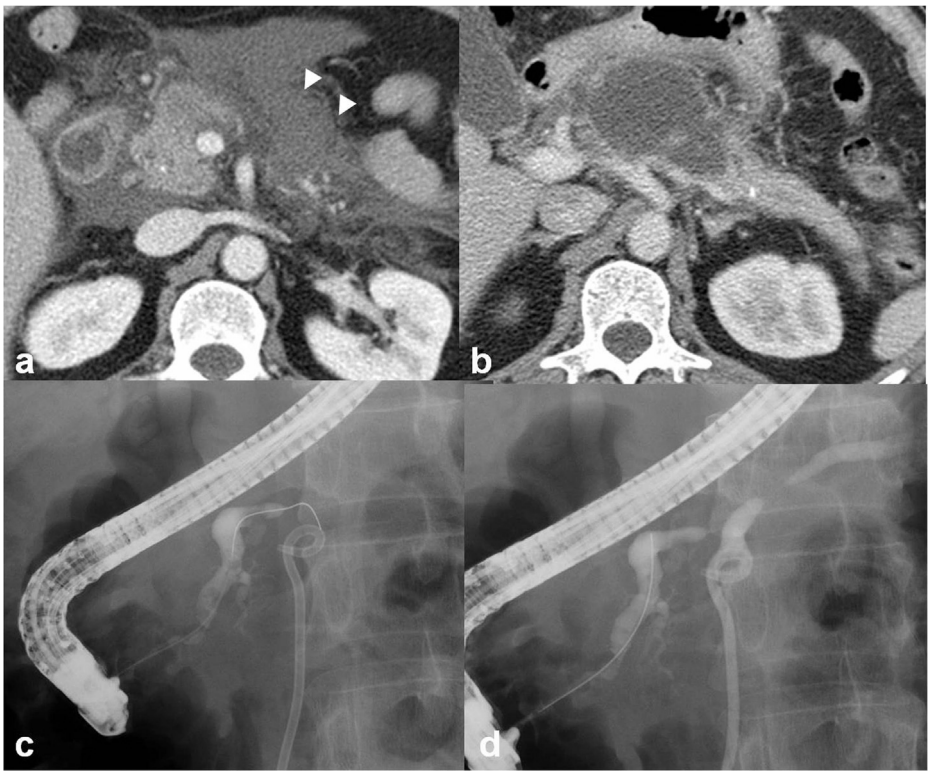

Fig. 3. Complete MPD disruption (DPDS). A 48-year-old male with AIDS. (a) initial CT showed necrosis in the body of the pancreas. (b) 1 month later, PFC developed despite the best conservative treatment and percutaneous catheter drainage was performed. (c) The pancreatogram showed complete cut-off (arrow) in the body portion of the MPD. (d) Injection of contrast medium through the percutaneous catheter identified the upstream MPD. Amylase-rich fluid drainage via the percutaneous catheter persisted with diet. Surgery was recommended, but the patient refused. He is under follow-up with the percutaneous catheter. MPD, main pancreatic duct; DPDS, disconnected pancreatic duct syndrome; AIDS, acquired immunodeficiency syndrome.

Downloaded from ClinicalKey.com at Italian Association of Gastroenterology (AIGO) December 26, 2016.
For personal use only. No other uses without permission. Copyright ©2016. Elsevier Inc. All rights reserved.

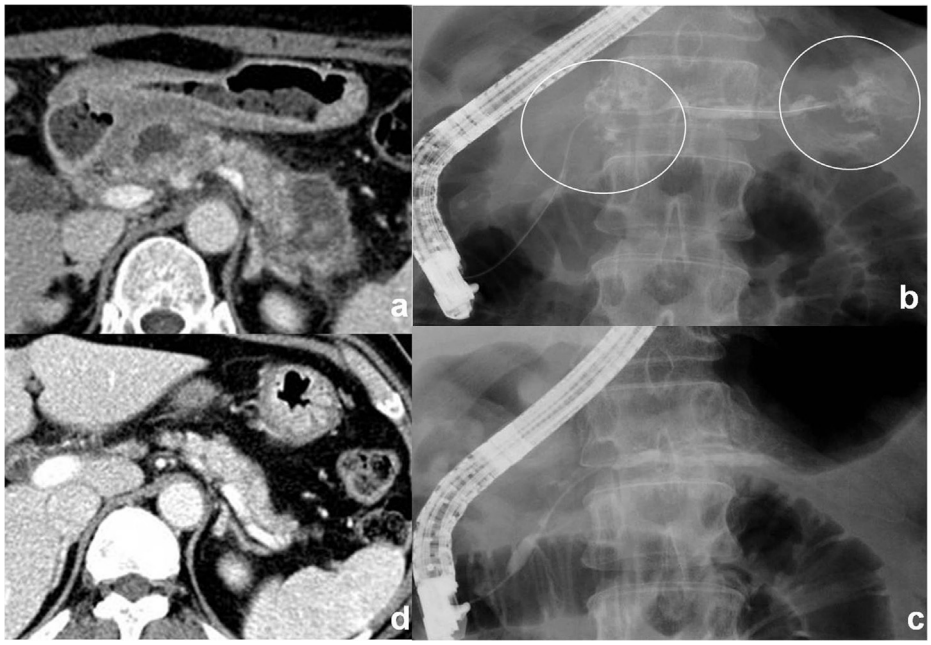

Fig. 4. Partial MPD disruption. A 49-year-old patient with ANP. (a) Walled-off necrosis developed in the neck and rail portion of the pancreas 6 weeks after ANP. (b) Stricture and leakage in the neck and tail portion of the MPD were noted on the pancreatogram (circles). (c) A follow-up pancreatogram performed after 3 months of placement of pancreatic stent showed no leakage but remained stricture of the neck portion; therefore, the plastic stent was reinserted. The stent was removed 6 months after the initial stent insertion, and (d) the final CT showed improvement of the walled-off necrosis.

2.5. Predictors and clinical consequences of complete MPD disruption compared with partial MPD disruption

The clinical and radiological characteristics were compared between the 14 ANP patients with complete MPD disruption and the 18 ANP patients with partial MPD disruption (Table 3). Pancreatic necrosis involving >50% of the area of the pancreas (100% vs. 50%, $p = 0.002$) and full-thickness glandular necrosis (86% vs. 28%, $p = 0.002$) were more frequently associated with complete MPD disruption.

Patients with complete MPD disruption had a lower success rate of endoscopic transpapillary stenting across the stricture site (20% vs 92%, $p = 0.010$), a higher incidence of recurrent/refractory PFCs or recurrence of pancreatitis after initial treatment (71% vs. 17%, $p = 0.003$), and a higher frequency of surgical treatment (43% vs. 6%, $p = 0.027$) when compared to patients with partial MPD disruption.

3. Discussion

Studies on the incidence of MPD disruption in ANP are very few

Table 3
Comparison between 14 ANP patients with complete MPD disruption and 18 ANP patients with partial MPD disruption (according to the type of disruption).

	Complete disruption (n = 14)	Partial disruption (n = 18)	P
Mean age (±SD), years	43 ± 17	47 ± 14	ns [£]
Gender, M:F	14:0	13:5	ns
Etiologies of ANP, n (%)			ns
Alcohol	9 (64)	5 (28)	
Other than alcohol	5 (36)	13 (72)	
Severity of acute pancreatitis, n (%)			ns
Moderately severe	10 (71)	14 (78)	
Severe	4 (29)	4 (22)	
Infected necrosis, n (%)	12 (86)	10 (56)	ns
Site of necrosis,n (%)			ns
Involving neck or proximal body	6 (43)	7 (39)	
Not involving neck or proximal body	8 (57)	11 (61)	
Extent of necrosis (>50%), n (%)	14 (100)	9 (50)	0.002
Full-thickness glandular necrosis, n (%)	12 (86)	5 (28)	0.002
Upstream duct dilatation distal to pancreatic necrosis, n (%)	4 (29)	3 (17)	ns
Need for ICU care, n (%)	6 (43)	5 (28)	ns
Mean hospital stay (±SD), days	49 ± 46	60 ± 43	ns
Successful transpapillary stenting, n (%)	1/5 (20)	11/12 (92)	0.010
Surgery for ANP treatment, n (%)	6 (43)	1[a] (6)	0.027
Recurrent/refractory PFCs or recurrence of pancreatitis after initial treatment, n (%)	10 (71)	3 (17)	0.003
Pancreatitis-related mortality, n (%)	0 (0)	1 (6)	ns
Mean follow-up period (±SD), days	973 ± 814	929 ± 923	ns

ANP, acute necrotizing pancreatitis; MPD, main pancreatic duct; SD, standard deviation; ns, not significant; ICU, intensive care unit; PFC, pancreatic fluid collections.
[a] One patient with partial MPD disruption underwent surgery, not because of a problem related to MPD disruption but owing to necrosectomy of uncontrolled infected necrosis.

Downloaded from ClinicalKey.com at Italian Association of Gastroenterology (AIGO) December 26, 2016.
For personal use only. No other uses without permission. Copyright ©2016. Elsevier Inc. All rights reserved.

in number, and interpretation of their results demands great caution. Uomo et al. reported an incidence of MPD disruption of 31% in ANP patients, but the cause of pancreatitis was limited to gallstones [11]. Lawrence et al. found a 16% incidence of disconnected pancreatic tail syndrome in 189 patients who underwent ERCP for an indication of PFCs or pancreatic fistulas [18]. Their study examined heterogeneous groups that included patients with acute pancreatitis, chronic pancreatitis, or post-surgical fistulas [18]. Our study demonstrated that incidence of MPD disruption was 38% in a homogeneous group of 84 ANP patients who underwent MRCP or ERCP in accordance with clinical need. Excluded 381 ANP patients from our study who did not undergo MRCP or ERCP on the basis of clinical need might have lowered risks of MPD disruption. Therefore, our study may have a potential for over-estimation on the incidence of MPD disruption in ANP patients because our study enrolled the group of patients with clinical suspicion on ductal disruption and need of further diagnostic evaluation or treatment such as MRCP or ERCP.

An MPD disruption may prolong the length of hospital stay due to unilateral pleural effusion, pancreatic ascites, or enlarging fluid collection [19,20]. Our study confirmed the prolongation of hospital stays in the MPD disruption group (mean 55 vs. 29 days). Our study also found a high rate of recurrent/refractory PFCs or recurrence of pancreatitis in the MPD disruption group (41% vs. 14%). However, the pancreatitis-related mortality or the need for intensive care unit care did not differ between ANP patients with and without MPD disruption.

Neoptolemos et al. found a persistent association between MPD disruption and extensive necrosis (>25%) that required surgical intervention. Lau et al. reported a 37% incidence of pancreatic ductal leak in severe acute pancreatitis and an association of ductal leak with pancreatic necrosis. Our study confirmed these results, as the development of MPD disruption in our ANP patients was significantly associated with extensive necrosis (>50%). In addition, enlarging/refractory PFCs, amylase-rich high-volume output from percutaneous drainage, or amylase-rich ascites/pleural effusion were significantly higher in our patients with MPD disruption. Mediastinal PFCs were only observed in the MPD disruption group. A high index of suspicion is important for early recognition of ongoing MPD disruption with leakage. The evaluation of MPD disruption should therefore be considered in the following presentations: 1) extensive pancreatic necrosis, 2) enlarging/refractory PFCs, 3) persistence of amylase-rich high-volume output from percutaneous drainage, 4) amylase-rich ascites/pleural effusion, or 5) mediastinal PFCs.

Initial ductal anatomy imaging (MRCP/ERCP) may be useful for determining whether the MPD is disrupted or disconnected. Although ERCP can be used identify MPD disruption in patients with ANP, possibly leading to interventions, no consensus has ever emerged that ERCP should be performed on a regular basis to confirm a duct leakage because of a concern regarding deterioration of underlying acute pancreatitis [10]. In the setting of ANP, ERCP for MPD evaluation carries the risk of infection of sterile necrosis by exacerbating a leak attributable to contrast injection at nonphysiologic pressure. ERCP can also be associated with post-procedure pancreatitis. In the setting of ANP, therefore, direct pancreatogram should be avoided early in the course of the disease (<2 weeks) except in the rare instance when this information may change the treatment plan for the patient (eg. severe gallstone pancreatitis) [17]. Transmural drainage rather than transpapillary drainage is generally performed first in patients with symptomatic large PFCs. After collections have resolved on follow-up CT, MRCP or ERCP can be performed to evaluate if pancreatic ductal disruption is present or not. One advantage noted after drainage of PFCs is that MRCP imaging of the MPD is often clarified, because these fluid collections no longer obscure the view.

MRCP for identifying MPD disruption may provide a secure basis for attempting a subsequent ERCP thereby obviating the need for routine direct pancreatograms. However, MRCP might have low sensitivity for detecting small disruptions [20]. In our study, the sensitivity of MRCP was 80% for detecting MPD disruption using ERCP as the gold standard. The sensitivity of MRCP was slightly higher in complete MPD disruption than in partial disruption (88% vs. 71%), but this difference was not statistically significant. These results suggest that MRCP can be strongly recommended for detecting ductal leakage as an initial modality because of its non-invasive nature. Secretin stimulation before MRCP can be used for better detection of ductal leakage because it significantly increased the sensitivity of detecting duct abnormalities in the setting of pancreatitis [21].

One strength of our study is its analysis of the predictors and clinical consequences of MPD disruption while discriminating between complete and partial disruption. DPDS is characterized by evidence of a complete MPD disruption and CT evidence of viable pancreatic tissue upstream, in association with a persistent pancreatic fistula or pancreatic-fluid collection [22]. DPDS has several clinical implications: First, it may affect the treatment outcome of endoscopic management for PFCs. In DPDS, endoscopic transpapillary stenting across the disruption site is almost impossible because of the complete separation of the upstream and downstream MPD. Our study also showed a lower success rate for endoscopic transpapillary stenting in patients with complete disruption (20% vs. 92%). Second, failed endoscopic transpapillary techniques are associated either with greater recurrence rates or the need for surgery [18]. Our study confirmed the higher rate of recurrent/refractory PFCs (71% vs. 17%) and a higher frequency of surgical treatment in complete disruption (43% vs 6%). Third, DPDS may affect the choice of initial drainage modality for PFCs. In the context of ANP, PFCs are often first drained percutaneously within the concept of step-up approach [10]. The percutaneous catheter drainage of PFCs should be avoided in DPDS patients because it transforms a collection easily accessible to transmural drainage into a permanent fistula with a high-grade of relapse when the percutaneous drainage is removed. In addition, initial percutaneous drainage may also render additional transmural drainage of the collection more difficult by reducing its size. In our study, 5 of 10 patients with DPDS and percutaneous drainage for a PFC could not remove their percutaneous catheter because of a permanent fistula with high output. Thus, in patients with DPDS, treatment could be initiated with transmural drainage rather than percutaneous drainage. Lastly, the likely recurrence of PFC after transmural stent removal is a concern if the stents are removed too early, despite active communication between the pancreatic-duct and the cavity [23]. The transmural stents could be left indefinitely even after PFC resolution, especially for patients with DPDS [9,24].

The differentiation between complete and partial MPD disruption is therefore relevant to gastroenterologists. Our study demonstrated the incidence of complete MPD disruption of 17% in ANP patients. Our study also found that extensive necrosis (>50%) and full-thickness glandular necrosis were significantly associated with complete MPD disruption. When ERCP is indicated by the 5 previously mentioned presentations and subsequent MRCP findings, we recommend performing ERCP with adequate-pressure contrast injection, especially in the presence of extensive necrosis or full-thickness glandular necrosis. This is because under-opacification of the MPD distal to the disruption may preclude accurate assessment of type of disruption (*i.e.*, complete vs. partial).

Our study had a few limitations. Due to its retrospective nature, we evaluated MPD integrity in selected patients on the basis of clinical need such as suspicion on ductal disruption. Moreover,

Downloaded from ClinicalKey.com at Italian Association of Gastroenterology (AIGO) December 26, 2016.
For personal use only. No other uses without permission. Copyright ©2016. Elsevier Inc. All rights reserved.

small MPD disruptions may not be detected in patients who underwent MRCP alone. However, these small disruptions may resolve spontaneously without symptoms and are less relevant in clinical practice. Clinicians also must be aware that a multidisciplinary approach that includes radiologic, endoscopic, and surgical intervention is often required to optimize outcomes when a ductal disruption occurs in an area of extensive necrosis [9,20].

In conclusion, MPD disruption is not uncommon in ANP patients with clinical suspicion on ductal disruption. The MPD disruption was more frequently detected in patients with extensive necrosis, enlarging/refractory PFCs, persistent drainage from percutaneous catheter, or amylase-rich ascites/pleural effusion. Associated MPD disruption may influence morbidity (prolonged hospital stay and recurrence of PFCs), but not mortality of patients with ANP. Patients with extensive necrosis and full-thickness glandular necrosis are more susceptible to DPDS. Complete MPD disruption is often treated by surgery, whereas partial MPD disruption can be managed successfully with endoscopic transpapillary stenting and/or transmural drainage. Further prospective studies are needed to study these items.

Author contributions

Ji Woong Jang was responsible for conception and design of the study, generation, collection, assembly, analysis and interpretation of data, and drafting of the manuscript; Myung-Hwan Kim was responsible for conception and design of the study, generation, collection, assembly, analysis and interpretation of data, revision of the manuscript, approval of the final version of the manuscript; Dongwook Oh was responsible for generation, collection, and assembly of data; Dong Hui Cho was responsible for collection and analysis of data; Tae Jun Song was responsible for generation of data and revision of the manuscript; Do Hyun Park was responsible for revision of the manuscript; Sang Soo Lee was responsible for generation of data and revision of the manuscript; Dong Wan Seo was responsible for generation of data and revision of the manuscript; Sung Koo Lee was responsible for generation of data and revision of the manuscript; Sung-Hoon Moon was responsible for conception and design of the study, generation, collection, assembly, analysis and interpretation of data, revision of the manuscript, approval of the final version of the manuscript.

Funding

No financial or other support was granted for this study.

Conflict of interest

None declared.

Appendix A. Supplementary data

Supplementary data related to this article can be found at http://dx.doi.org/10.1016/j.pan.2016.09.009.

References

[1] Neoptolemos JP, London NJ, Carr-Locke DL. Assessment of main pancreatic duct integrity by endoscopic retrograde pancreatography in patients with acute pancreatitis. Br J Surg 1993;80:94–9.
[2] Kozarek RA, Ball TJ, Patterson DJ, Freeny PC, Ryan JA, Traverso LW. Endoscopic transpapillary therapy for disrupted pancreatic duct and peripancreatic fluid collections. Gastroenterology 1991;100:1362–70.
[3] Huibregtse K, Schneider B, Vrij AA, Tytgat GN. Endoscopic pancreatic drainage in chronic pancreatitis. Gastrointest Endosc 1988;34:9–15.
[4] Buchler M, Friess H, Klempa I, Hermanek P, Sulkowski U, Becker H, et al. Role of octreotide in the prevention of postoperative complications following pancreatic resection. Am J Surg 1992;163:125–30. discussion 30–1.
[5] Huckfeldt R, Agee C, Nichols WK, Barthel J. Nonoperative treatment of traumatic pancreatic duct disruption using an endoscopically placed stent. J Trauma 1996;41:143–4.
[6] Baron TH, Harewood GC, Morgan DE, Yates MR. Outcome differences after endoscopic drainage of pancreatic necrosis, acute pancreatic pseudocysts, and chronic pancreatic pseudocysts. Gastrointest Endosc 2002;56:7–17.
[7] Varadarajulu S, Rana SS, Bhasin DK. Endoscopic therapy for pancreatic duct leaks and disruptions. Gastrointest Endosc Clin N Am 2013;23:863–92.
[8] Nealon WH, Bhutani M, Riall TS, Raju G, Ozkan O, Neilan R. A unifying concept: pancreatic ductal anatomy both predicts and determines the major complications resulting from pancreatitis. J Am Coll Surg 2009;208:790–9. discussion 9–801.
[9] Freeman ML, Werner J, van Santvoort HC, Baron TH, Besselink MG, Windsor JA, et al. Interventions for necrotizing pancreatitis: summary of a multidisciplinary consensus conference. Pancreas 2012;41:1176–94.
[10] Tenner S, Baillie J, DeWitt J, Vege SS. American college of gastroenterology guideline: management of acute pancreatitis. Am J Gastroenterol 2013;108:1400–15. 16.
[11] Uomo G, Molino D, Visconti M, Ragozzino A, Manes G, Rabitti PG. The incidence of main pancreatic duct disruption in severe biliary pancreatitis. Am J Surg 1998;176:49–52.
[12] Banks PA, Bollen TL, Dervenis C, Gooszen HG, Johnson CD, Sarr MG, et al. Classification of acute pancreatitis–2012: revision of the atlanta classification and definitions by international consensus. Gut 2013;62:102–11.
[13] Balthazar EJ, Robinson DL, Megibow AJ, Ranson JH. Acute pancreatitis: value of ct in establishing prognosis. Radiology 1990;174:331–6.
[14] Strasberg SM, McNevin MS. Results of a technique of pancreaticojejunostomy that optimizes blood supply to the pancreas. J Am Coll Surg 1998;187:591–6.
[15] Kawakami H, Itoi T, Sakamoto N. Endoscopic ultrasound-guided transluminal drainage for peripancreatic fluid collections: where are we now? Gut Liver 2014;8:341–55.
[16] Shyu JY, Sainani NI, Sahni VA, Chick JF, Chauhan NR, Conwell DL, et al. Necrotizing pancreatitis: diagnosis, imaging, and intervention. Radiographics 2014;34:1218–39.
[17] Nadkarni NA, Kotwal V, Sarr MG, Swaroop Vege S. Disconnected pancreatic duct syndrome: endoscopic stent or surgeon's knife? Pancreas 2015;44:16–22.
[18] Lawrence C, Howell DA, Stefan AM, Conklin DE, Lukens FJ, Martin RF, et al. Disconnected pancreatic tail syndrome: potential for endoscopic therapy and results of long-term follow-up. Gastrointest Endosc 2008;67:673–9.
[19] Lau ST, Simchuk EJ, Kozarek RA, Traverso LW. A pancreatic ductal leak should be sought to direct treatment in patients with acute pancreatitis. Am J Surg 2001;181:411–5.
[20] Wu BU, Banks PA. Clinical management of patients with acute pancreatitis. Gastroenterology 2013;144:1272–81.
[21] Sherman S, Freeman ML, Tarnasky PR, Wilcox CM, Kulkarni A, Aisen AM, et al. Administration of secretin (rg1068) increases the sensitivity of detection of duct abnormalities by magnetic resonance cholangiopancreatography in patients with pancreatitis. Gastroenterology 2014;147:646–54. e2.
[22] Pelaez-Luna M, Vege SS, Petersen BT, Chari ST, Clain JE, Levy MJ, et al. Disconnected pancreatic duct syndrome in severe acute pancreatitis: clinical and imaging characteristics and outcomes in a cohort of 31 cases. Gastrointest Endosc 2008;68:91–7.
[23] Arvanitakis M, Delhaye M, Bali MA, Matos C, De Maertelaer V, Le Moine O, et al. Pancreatic-fluid collections: a randomized controlled trial regarding stent removal after endoscopic transmural drainage. Gastrointest Endosc 2007;65:609–19.
[24] Devière J, Antaki F. Disconnected pancreatic tail syndrome: a plea for multidisciplinarity. Gastrointest Endosc 2008;67:680–2.

Downloaded from ClinicalKey.com at Italian Association of Gastroenterology (AIGO) December 26, 2016.
For personal use only. No other uses without permission. Copyright ©2016. Elsevier Inc. All rights reserved.